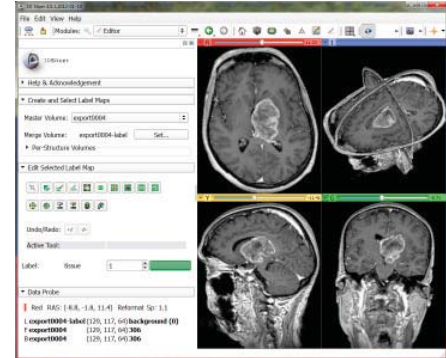


Capability of the Medical Image Computing Platform *3D Slicer* for Glioblastoma Multiforme Segmentation in Magnetic Resonance Imaging (MRI) Data

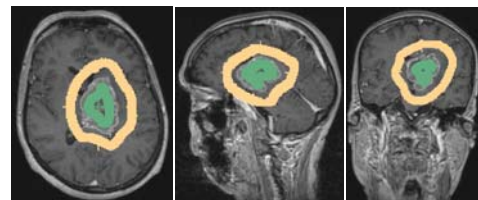
Jan Egger, Ph.D., Ph.D.^{a,b,c}, Tina Kapur, Ph.D.^a, Andriy Fedorov, Ph.D.^a, Steve Pieper Ph.D.^{a,d}, James V. Miller, Ph.D.^e, Harini Veeraraghavan, Ph.D.^f, Bernd Freisleben, Ph.D.^c, Alexandra J. Golby, M.D.^{a,g}, Christopher Nimsky, M.D., Ph.D.^b and Ron Kikinis, M.D.^a

^a Dept. of Radiology, Surgical Planning Lab, Brigham and Women's Hospital Boston, MA, USA, ^b Dept. of Neurosurgery, University of Marburg, Marburg, Germany, ^c Dept. of Mathematics and Computer Science, University of Marburg, Marburg, Germany, ^d Isomics, Inc., Cambridge, MA, USA, ^e Interventional and Therapy Lab, GE Research, Niskayuna, NY, USA, ^f Biomedical Image Analysis Lab, GE Research, Niskayuna, NY, USA, ^g Dept. of Neurosurgery, Brigham and Women's Hospital, Harvard Medical School, Boston, MA, USA

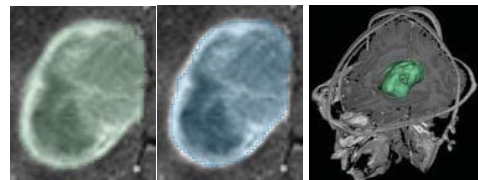
Purpose – Gliomas are the most common primary brain tumors, evolving from the cerebral supportive cells. The World Health Organization (WHO) grading system for gliomas defines grades I-IV, where grade I tumors are the least aggressive and IV are the most aggressive [1]. 70% belong to the group of malignant gliomas (anaplastic astrocytoma grade III, glioblastoma multiforme grade IV). The glioblastoma multiforme, named for its histopathological appearance, is the most frequent malignant primary tumor and is one of the most highly malignant human neoplasms. Volumetric change in grade IV tumors (glioblastoma multiforme (GBM)) over time is a critical factor in treatment decisions by physicians. Typically, the tumor volume is computed on a slice-by-slice basis using MRI patient scans obtained at regular intervals. In this contribution we investigated the capability of the medical image computing platform *3D Slicer* for the segmentation of GBMs.



Methods – For this study, we used the *GrowCut* [2] software module in *3D Slicer* [3], which is freely downloadable from the website <http://www.slicer.org>. The upper image shows the *3D Slicer* interface with the *Editor* on the left side and a loaded GBM data set on the right side: axial slice (upper left window), sagittal slice (lower left window), coronal slice (lower right window) and the three slices shown in a 3D visualization (upper right window). A typical user initialization of *GrowCut* under *Slicer* for the segmentation of a GBM is presented in the three images on the right side: axial (left image), sagittal (middle image) and coronal (right image). Note: the tumor has been initialized in green and the background has been initialized in yellow.



Results – In this study, four physicians segmented GBMs in ten patients, once using the competitive region-growing based *GrowCut* segmentation module of *3D Slicer*, and once purely by drawing boundaries completely manually on a slice-by-slice basis. The time and user effort required for *GrowCut* segmentation was on an average 25% compared to pure manual segmentation. A comparison of *Slicer* based segmentation with manual slice-by-slice segmentation resulting in a *Dice Similarity Coefficient* [4] of $88.43 \pm 5.23\%$ and a *Hausdorff Distance* of $2.32 \pm 5.23\text{mm}$ shows that the two are comparable. The two left images of this section show a comparison of GBM segmentation results on an axial slice: semi-automatic segmentation under *Slicer* (green, left image) and pure manual segmentation (blue, middle image). The right image presents a 3D segmentation result of *GrowCut* (green). After the initialization of the *GrowCut* algorithm under *Slicer* it took about ten seconds to get the segmentation result on an *Intel Core i7-990 CPU, 12x3.47 GHz, 12 GB RAM, Windows 7 Home Premium x64 Version, Service Pack 1*.



Conclusions – In this study we evaluated the capability of *3D Slicer* for segmentation of GBMs compared to manual slice-by-slice segmentation. As a metric for our evaluation we used the agreement between slice-by-slice and *Slicer* segmentations to show that *Slicer* can be used to produce GBM segmentations that are statistically equivalent to what the physicians achieve manually in fraction of the time (0.25). Areas of future work include a direct comparison of the *Slicer*-based segmentation with a graph-based algorithm [5], and extension to multi-modal images.

Acknowledgements

The authors want to thank the members of the Slicer Community for their contributions and furthermore the physicians Dr. med. Daniela Kuhnt, Dr. med. Barbara Carl, Christoph Kappus and Rivka Colen, M.D. for participating in this study. This work was supported by National Institutes of Health (NIH) grant P41EB015898.

References

- [1] P. Kleihues, et al., The WHO classification of tumors of the nervous system, *Journal of Neuropathology & Experimental Neurology*, 61(3):215-229, 2002.
- [2] V. Vezhnevets and V. Konouchine, *GrowCut* - Interactive multi-label N-D image segmentation, in *Proc. Graphics*, pp. 150-156, 2005.
- [3] *GrowCut*-Module under 3DSlicer <http://www.slicer.org/slicerWiki/index.php/Modules:GrowCutSegmentation-Documentation-3.6>
- [4] K. H. Zou, et al., Statistical Validation of Image Segmentation Quality Based on a Spatial Overlap Index: *Scientific Reports*, *Academic Radiology*, 11(2), pp. 178-189, 2004.
- [5] J. Egger, B. Freisleben, C. Nimsky, and T. Kapur, *Template-Cut: A Pattern-Based Segmentation Paradigm*, *Nature - Scientific Reports*, *Nature Publishing Group (NPG)*, 2(420), 2012.